Gastrointestinal tract
GIT-207

Parasitic infections of the small intestine

by
Dr. Noha Hamed
Dr: Nahed Elossily
Professors of Medical Parasitology
Merit University

Intellectual learning objectives:

1. **Identify and classify** the major helminths and protozoa that infect the small intestine (e.g., Heterophyes heterophyes, Taenia spp., Diphyllobothrium latum, Hymenolepis nana, *Ascaris*, *Ancylostoma*, *Trichinellan Strongyloides*, *Giardia and Crytosporidium*)
2. **Recall the life cycles** of key parasites, specifically identifying the **infective stage** and the **mode of transmission** for each
3. **Analyze the pathogenesis and Differentiate between the clinical phases and complications of each** parasitic infections
4. **Evaluate diagnostic findings** to select the appropriate laboratory test
5. **Design prevention and control strategies** based on the epidemiological distribution and reservoir hosts of specific parasites,

Parasitic infections of the small intestine

Helminthes	Protozoa
1. *Heterophes heterophyes*	1. *Giardia intestinalis (G. lamblia)*
2. *Hymenolepis nana*	2. *Cryptosporidium parvum*
3. *Taenia saginata*	
4. *Taenia solium*	
5. *Diphyllobothrium latum*	
6. *Ascaris lumbercoides*	
7. *Ancylostoma duodenale*	
8. *Capillaria philippinensis*	
9. *Trichinella spiralis*	
10. *Strongyloides stercorali*	

1. Heterophyes heterophyes

Geographical distribution:	➢ Common in Egypt mainly in the lakes of Delta (brackish water), the Mediterranean basin, Middle and Far East.
Habitat	➢ between the villi of the small intestine.
Definitive host	➢ Man
Reservoir host	➢ Cat, dog and any fish-eating animals.
Intermediate hosts	➢ 1st : Pirenella conica snails. ➢ 2nd is fish, Tilapia (Bolty) and Mugil (Boury).
Infective stage	➢ Encysted metacercaria in the fish muscle.
Mode of infection:	➢ By eating insufficient cooked, roasted or salted fish (sweet fesekh), containing the infective stage (encysted metacercariae).

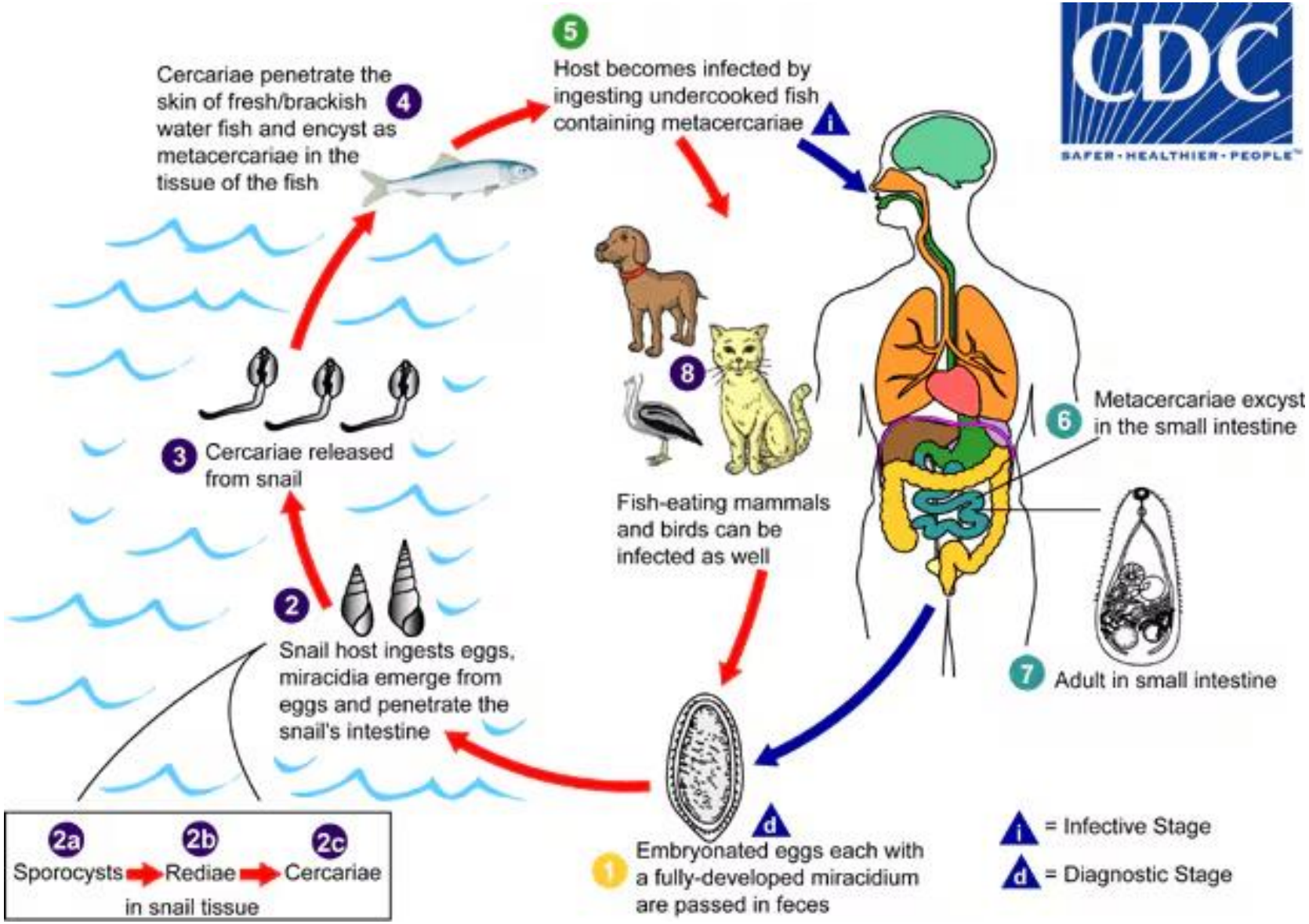
CDC
SAFER · HEALTHIER · PEOPLE™
5
Host becomes infected by ingesting undercooked fish containing metacercariae
i
Cercariae penetrate the skin of fresh/brackish water fish and encyst as metacercariae in the tissue of the fish
4
3
Cercariae released from snail
8
Fish-eating mammals and birds can be infected as well
6
Metacercariae excyst in the small intestine
7
Adult in small intestine
2
Snail host ingests eggs, miracidia emerge from eggs and penetrate the snail's intestine
2a
Sporocysts
2b
Rediae
2c
Cercariae
in snail tissue
d
1
Embryonated eggs each with a fully-developed miracidium are passed in feces
i = Infective Stage
d = Diagnostic Stage

Pathogenesis: Attachment of the parasite to the mucosal membranes lead to inflammation with superficial ulcers and necrosis .

clinical picture:

1. Mild infection: no symptoms
2. Heavy infections: Abdominal colic and discomfort, chronic intermittent diarrhea, sometimes with blood.
3. Extra-intestinal complications: The eggs may embolize in the CNS.

Diagnosis:

Stool examination for detection the characteristic minute operculated eggs.

Heterophyes heterophyes

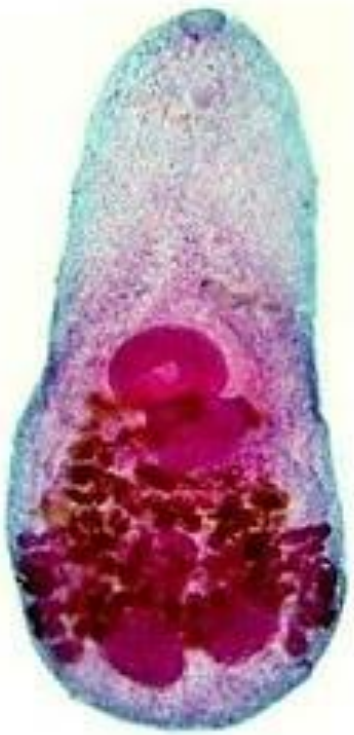

Heterophyes heterophyes
Adult I

Egg: small, operculated, yellowish brown, thick shell

Control:

1. proper cooking of fish.
2. Fish should be salted for at least 7 – 10 days.
3. Freezing of fish for few days kill metacercariae.
4. Prevention of pollution of lakes water by fishermen faeces.
5. Treatment of infected final hosts.
6. Destruction of the snail intermediate host (***Pirenella conica*** is a bottom feeder snail that is not easily affected by molluscides).

Treatment: Drug of choice is Praziquantel, 25-mg/kg-body weight 3 times daily for one day.

2- *Hymenolepis nana* (Dwarf tape worm)

Geog. Dist.	cosmopolitan. It is the commonest tape worm in children.
Def. host (D.H)	Man acts as definitive as well as intermediate host.
Habitat	Small intestine.
Inter. hosts (I.H)	various species of beetles and fleas
Infective stage	Eggs
Mode of infection:	1. Ingestion of eggs with contaminated food or drink. 2. Accidental swallowing of infected insect intermediate hosts (indirect cycle). 3. Autoinfection: it may be: · External autoinfection, hand to mouth. · Internal autoinfection when eggs hatch in the GIT leading to hyper-infection.

Life cycle: Hymenolepis

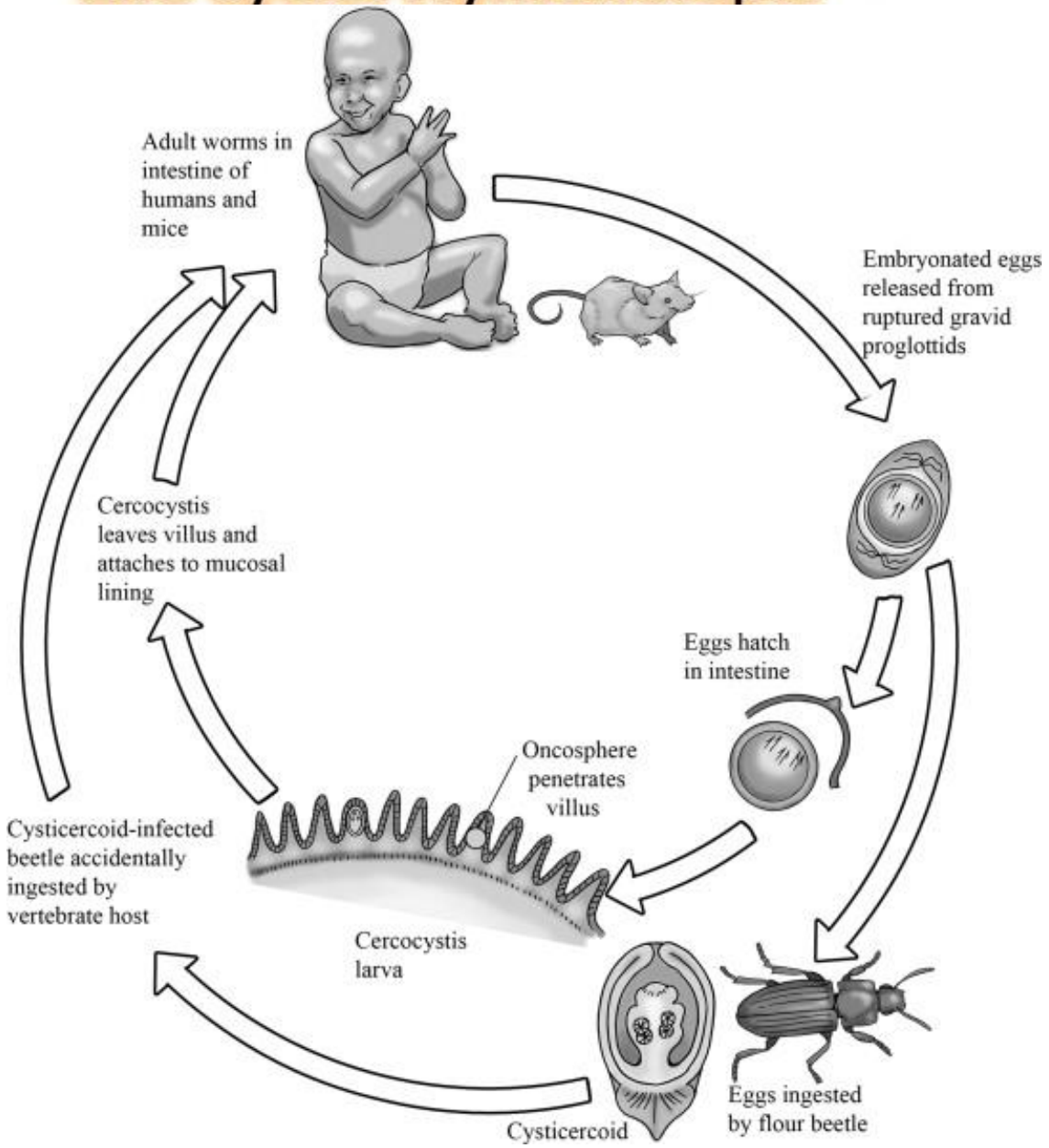

Pathogenesis and clinical picture

1. In heavy infections: ulcerations of the mucosa lead to enteritis. There may be abdominal discomfort, colic and diarrhea.
2. Some patients specially children suffer from dizziness and may be **convulsion, attributed to neurotoxin product of the worms.**

Diagnosis:

1. Direct by finding eggs in faces.
2. Serological diagnosis: ELISA

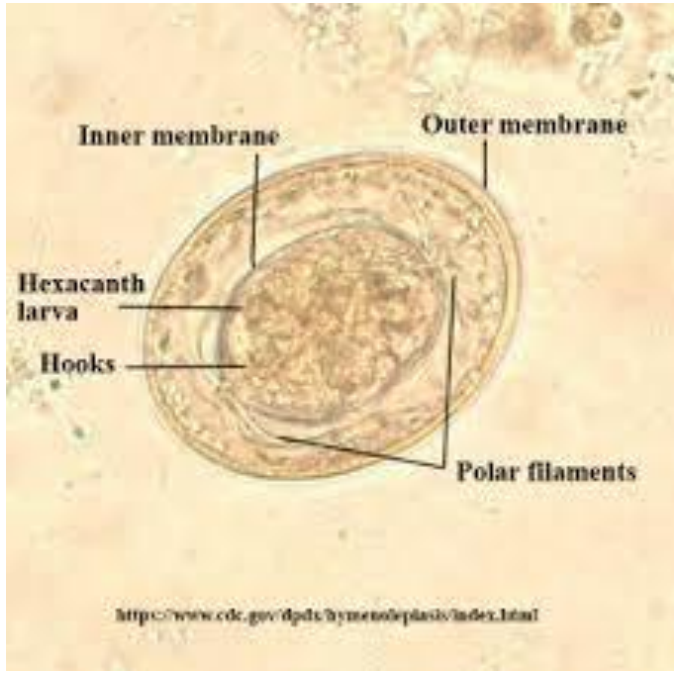

3- Taenia saginata (Beef tapeworm)

The disease	Taeniasis saginata
Geographical distribution	Worldwide and more common in Islamic countries (sheep raising countries).
Host	Found only in man (host specific). .
Intermediate host	Cattle.
Habitat	Small intestine.
Infective stage	Cysticercus bovis
Mode of infection	by ingestion of Cysticercus bovis in undercooked cattle meat
Diagnostic stage	Gravid segment which pass single with or without defecation as well as eggs in stool.

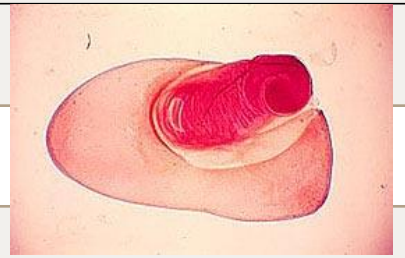

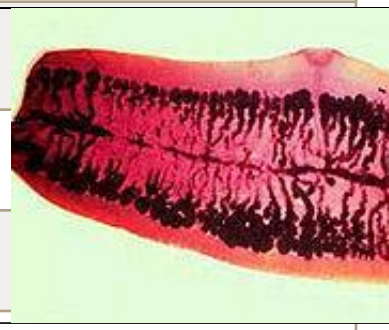

THE LIFE CYCLE of *Taenia saginata*

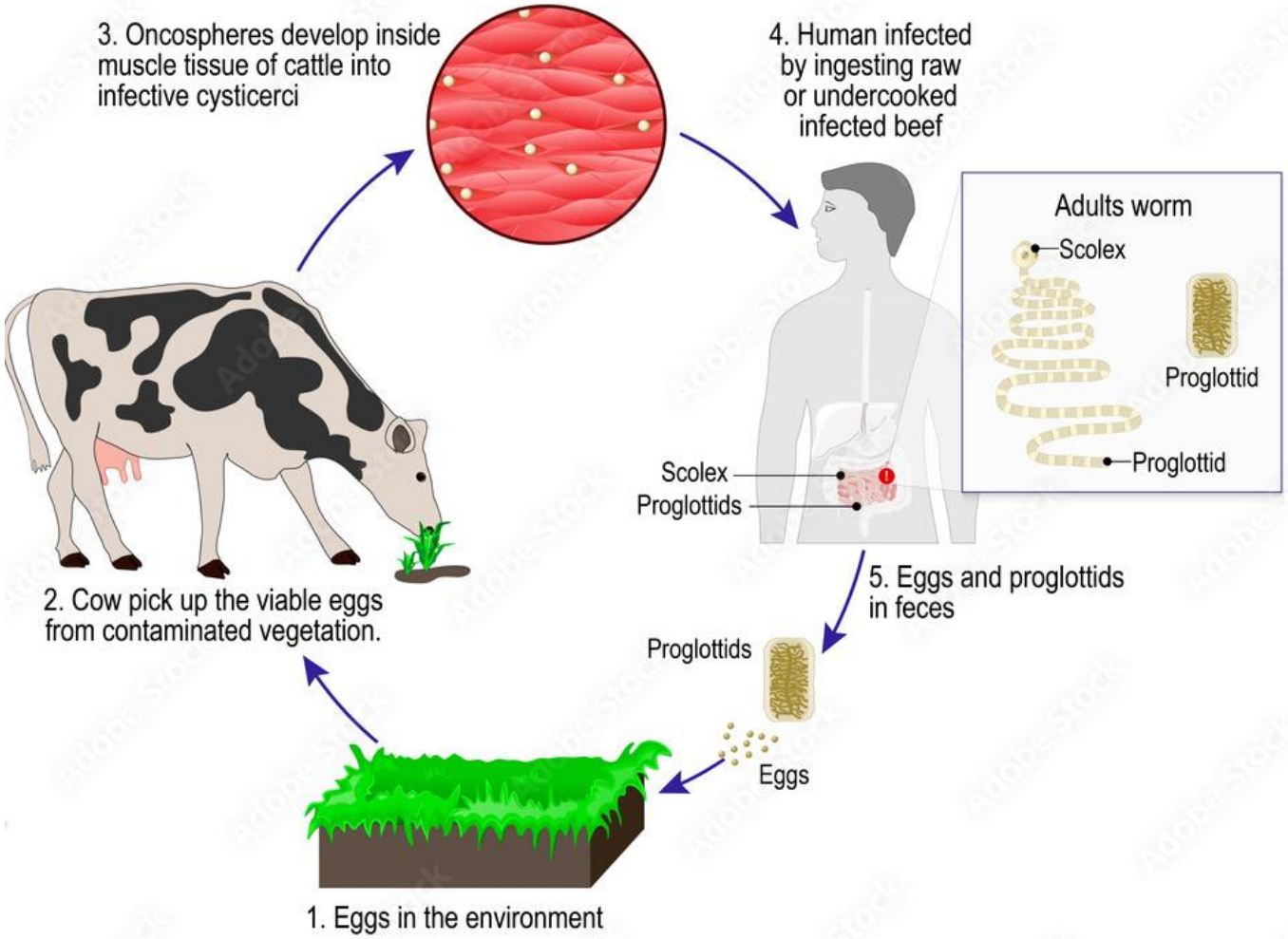

Pathogenesis and clinical picture

1. Most cases are asymptomatic.
2. Intestinal disturbances as hunger pain, indigestion, abdominal discomfort, diarrhea or constipation
3. Malnutrition and avitaminosis.
4. Loss of weight and appetite.
5. Segments of *T. saginata* migrating out of the anus cause perianal itching (pruritis ani), irritation, insomnia and anxiety.

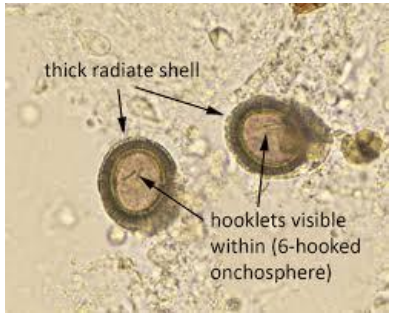

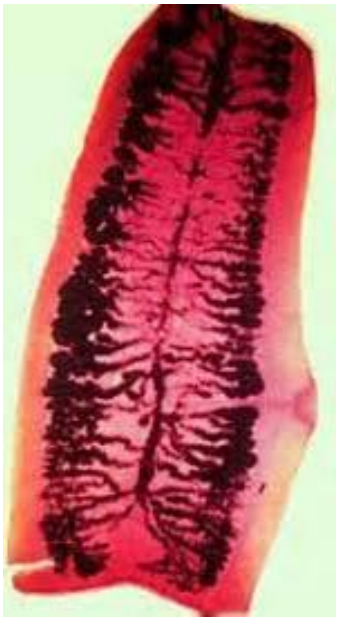

Diagnosis:

finding eggs or gravid segment (15 – 30 uterine branches) in the faeces. Single gravid segments may crawl outside the anus (without stools).

4- *Taenia solium* (Pork tapeworm)

The disease	*Taeniasis solium, Cysticercosis*
Geog. distribution	Worldwide, especially in pig raising countries.
Host	Found only in man (host specific).
Intermediate host	Pig and occasionally man (cysticercosis).
Habitat	Small intestine.
Infective stage	➢ Cysticercus cellulosae ……. Taeniasis solium ➢ Egg…….cysticercosis
Mode of infection	➢ Adult worm: by ingestion of Cysticercus cellulosae in undercooked pork meat ➢ Cysticercosis by ingestion of egg by autoinfection or with contaminated food and water
Diagnostic stage	gravid segments which come out with stool in a chain of 2-3 segments. The eggs are rarely present in stool and are similar to those of Taenia saginata but they are not acid fast.

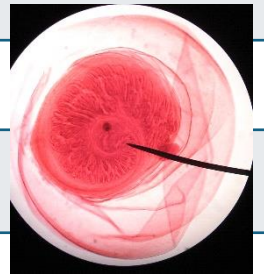

Life cycle of *T. solium*

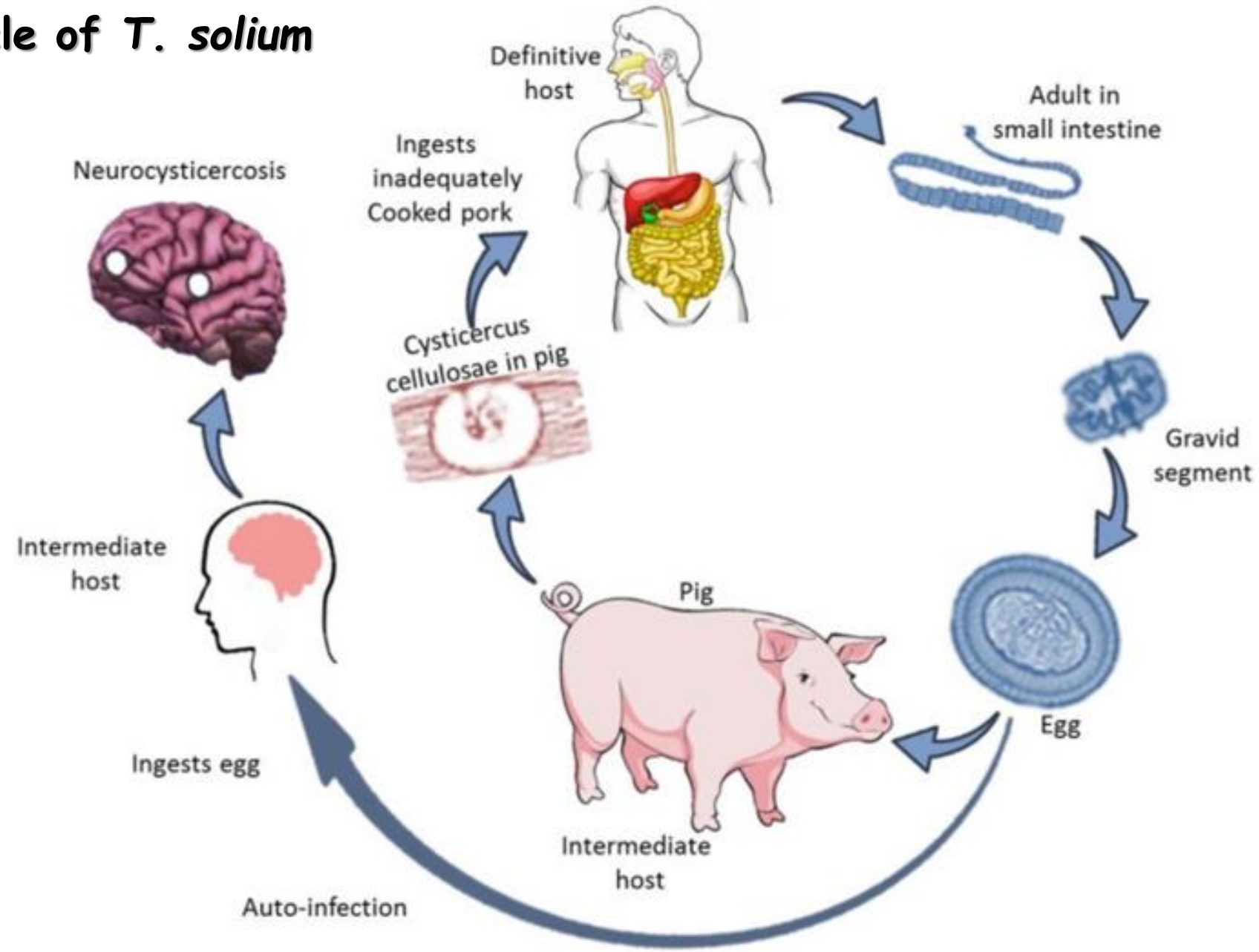

Pathogenesis and clinical Picture

1. Taeniasis solium: Man ingests *Cysticercus cellulosea* in pig's muscles and the adult parasite develops. The disease is like taeniasis saginata.
2. **Cysticercosis: Man ingests eggs of *T. solium* and develops *Cysticercus cellulosa* in the extra- intestinal tissues as liver.**

Diagnosis:

Laboratory diagnosis:

1. Direct detection of eggs or gravid segments (with 7 – 13 uterine branches) in stool. Gravid segments usually come out in chains of 2 –3 segments only with faeces. .

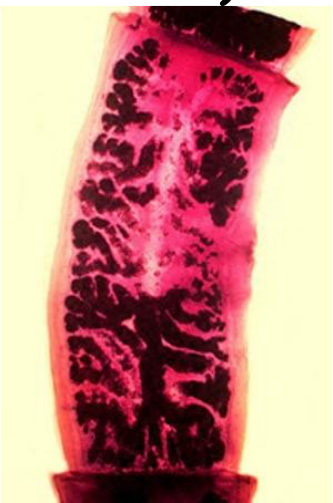

2. Serological diagnosis by ELISA.

5. Diphyllobothrium latum (Fish tapeworm)

Geographical distribution	**Russia, Europe, Japan, Central Africa and North America. It is not recorded in Egypt**
Host	➢ Fish eating mammals (reservoir hosts) ➢ Man
Intermediate host	1st : Cyclops (water flea) 2nd : freshwater fish (salmon & cyprinoid fish)
Habitat	Small intestine.
Infective stage	**plerocercoid**
Mode of infection	Eating insufficiently cooked or insufficiently pickled fish infected with **plerocercoid**
Diagnostic stage	immature eggs in stool.

Life cycle of D. latum

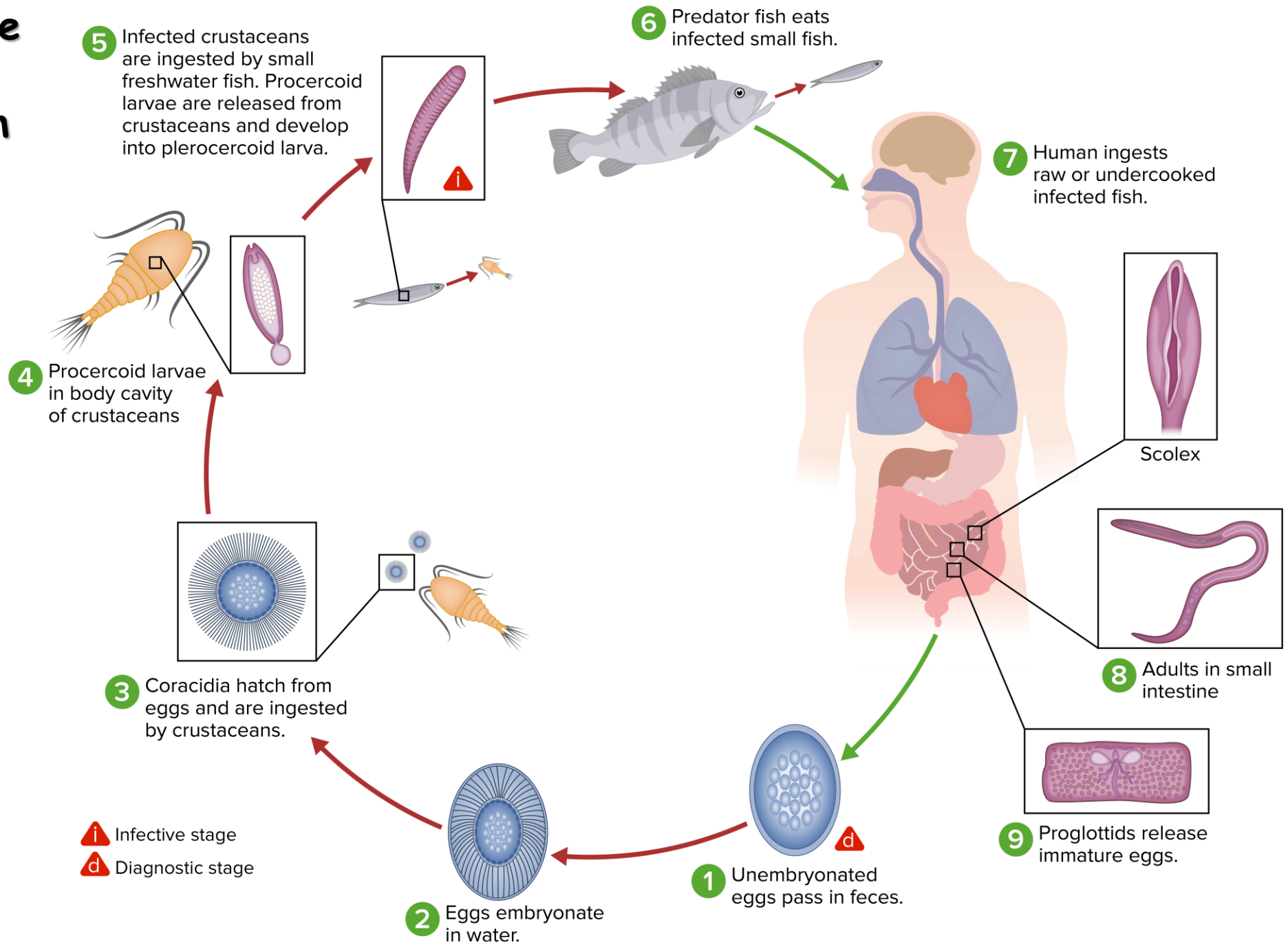

Pathogenesis and clinical picture:

- Abdominal pain, discomfort, nausea, vomiting, diarrhea, weakness and loss of weight.
- Eosinophilia and **macrocytic megaloblastic anaemia** due to absorption of unsaturated fatty acid liberated by the worm and tendency of the worm to pick up vitamin B12 and folic acid.
- Intestinal obstruction may occur.

Diagnosis:

1. Clinical symptoms.
2. Examination of the faces to reveal the eggs (differential diagnosis from ***Fasciola*** eggs).

6. *Ascaris lumbricoides*
(Giant intestinal roundworm)

The disease	Ascariasis
Geog. distribution	Worldwide.
Host	Man.
Habitat	free in the small intestine
Infective stage	Embryonated eggs (contain rhabditiform larva)
Mode of infection	by ingestion of **embryonated eggs** with contaminated food or water
Diagnostic stage	Fertilized egg The egg may be unfertilized

Life cycle of *Ascaris lumbricoides*

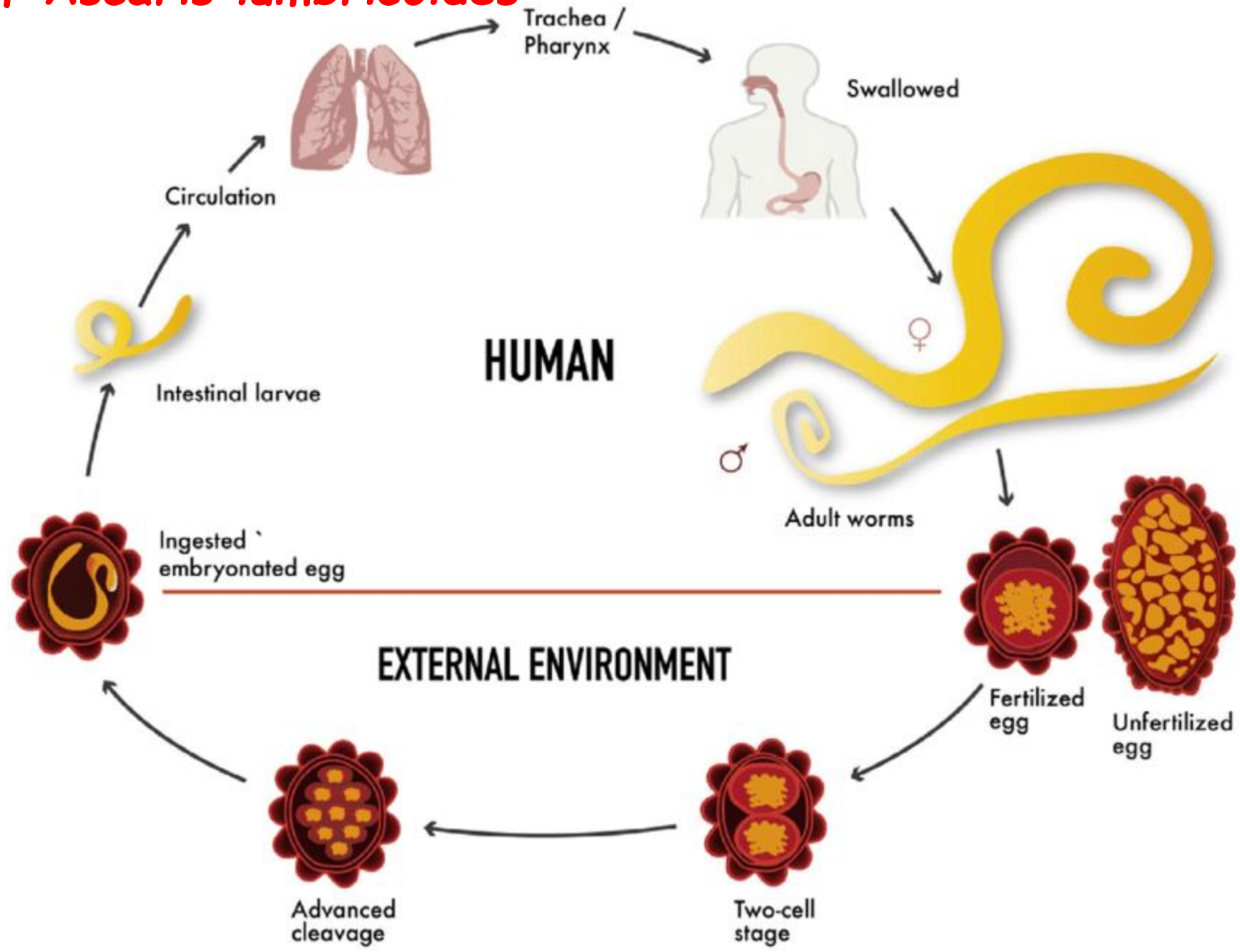

Pathogenicity and clinical picture:

Clinical manifestations in ascariasis can be caused either by the migrating larvae or by the adult worms.

A. Migrating larvae: pneumonia, cough, low-grade fever and 30% to 50% eosinophilia **(Löffler's syndrome)** result from migration of larvae through the lungs.

B. Adult worm:

1. Abdominal discomfort, colic, dyspepsia, vomiting, diarrhea or constipation.
2. Toxic or allergic effects: By-products of living or dead worms may produce allergic manifestations,
3. Impairment of growth
4. The worms produce a trypsin-inhibiting substance, which interferes with digestion of protein

c. Complication and or erratic parasite

1. Heavy infection causes intestinal obstruction.
2. Obstruction of the bile ducts by the worm.
3. **appendicitis**
4. Obstruction of ampulla of Vater causing acute hemorrhagic pancreatitis.
5. Perforation of intestinal wall result in peritonitis

Diagnosis:

1. Detection of eggs in the stool (fertilized, unfertilized, corticated or decorticated).
2. Detection of larvae in the sputum and Charcot Leyden crystals early in the disease (Löffler's syndrome).
3. Accidental expulsion of the worms in vomitus or stool.
4. High eosinophilia.
5. X-ray on abdomen after barium meal reveals worms as filling defects or as string-like shadows when they swallow the opaque substance (Tramway sign).

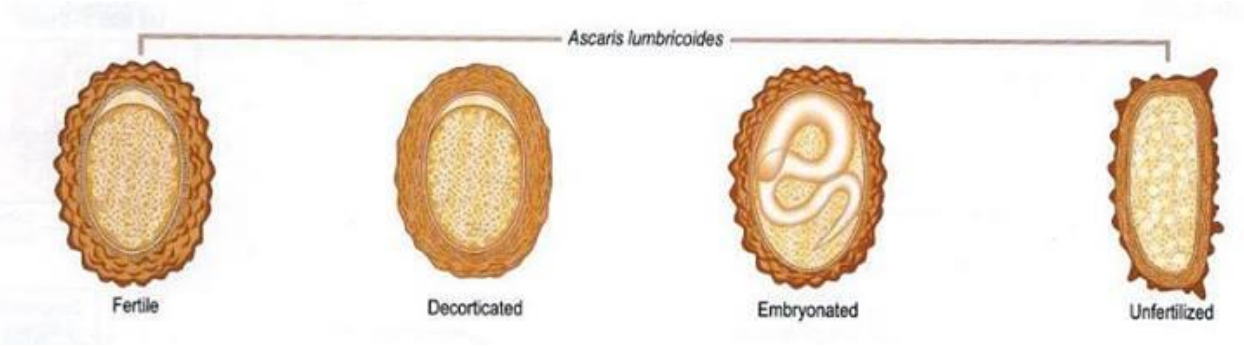

8. hookworms (bursated nematodes)
Ancylostoma duodenale and Necator americanus (the new world hookworm)

Geog. distribution	• Both *N. americanus* and *A. duodenale* are found in Africa, Asia, Australia and the Americas. • while only *A. duodenale* is found in the Middle East, North Africa, and northern India.
Host	Man.
Habitat	small intestine
Infective stage	3rd stage larva (filariform larvae)
Mode of infection	by penetration of the skin or mucous membrane by **filariform larvae** on walking bare footed on contaminated soil or drinking contaminated water
Diagnostic stage	Immature egg

Life cycle of hookworms

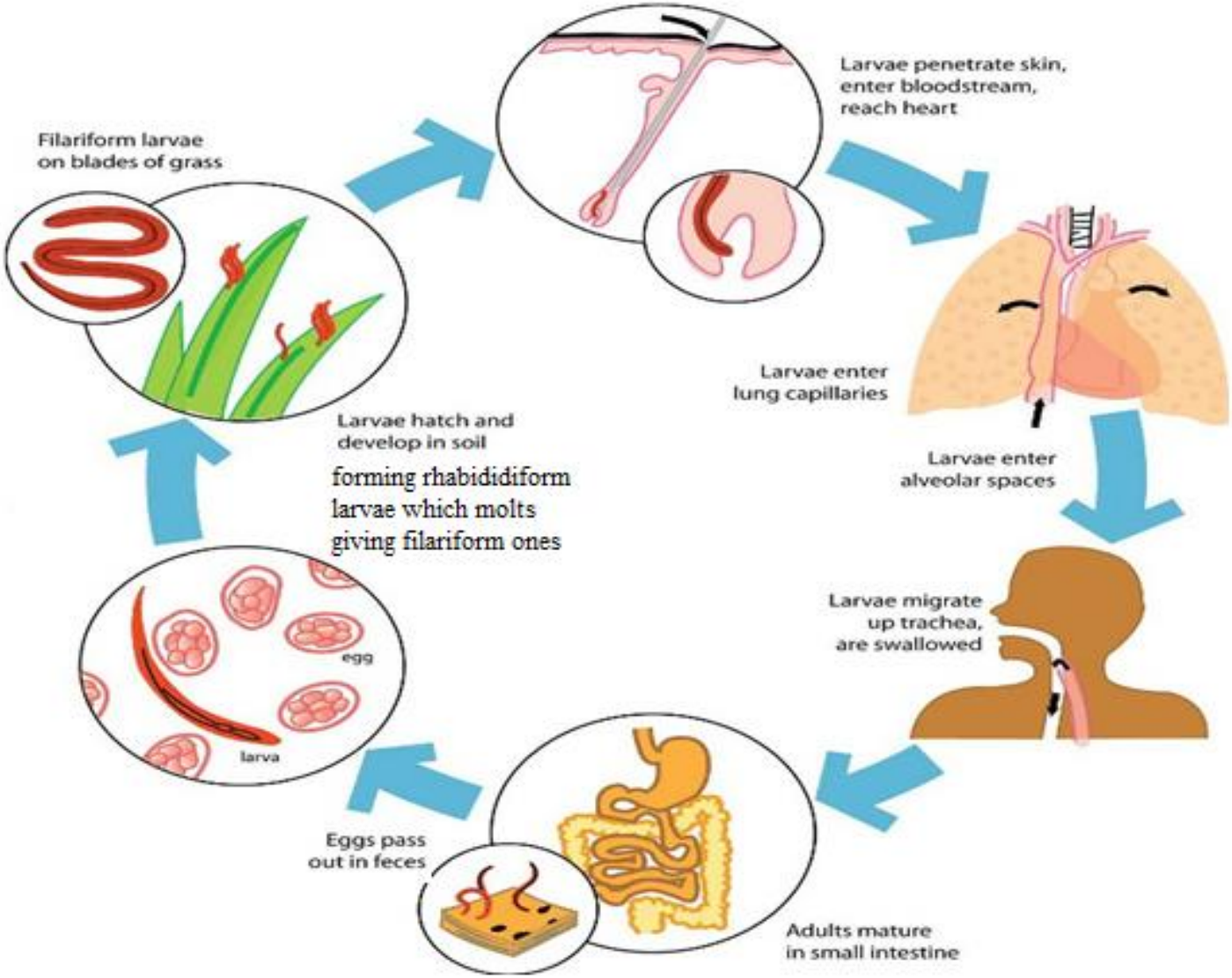

Pathology and clinical picture:

A. Penetration of the skin: ground itch a localized itchy rash at the site of larval penetration, redness and swelling may be complicated by secondary bacterial infection

B. Loffler's syndrome: cough, chest pain expectoration of sputum tined with blood

C. Intestinal stage: Manifestation depends on the number of worms and nutritional status of the infected person:

1. Epigastric pain, flatulence, nausea, vomiting, diarrhea and or constipation.

2. Anemia (microcytic hypochromic) Pallor, palpitation, dyspnea on exertion and easy fatigability

3. Physical and mental retardation may occur especially in young children due to anemia and hypoproteinaemia

8. *Trichinella spiralis*

Disease	Trichnillosis
Geog. distribution	Worldwide, It is common in pork eating countries.
Host	Rats, pigs are natural hosts. Man is an accidental host. The same animal and man act as final and intermediate host harboring the adult parasite and the larvae.
Habitat	Adult male and female inhabit the small intestine. Larvae are encysted in the muscles of the same host especially active ones as muscles of **tongue, deltoid, diaphragm and muscles of mastication** .
Infective stage	Encysted larvae in muscle
Mode of infection	Man is infected by ingestion of raw or undercooked pork meat containing **infective (viable) encysted larvae**.
Diagnostic stage	Encysted larvae in muscle

Life cycle of *Trichinella spiralis*

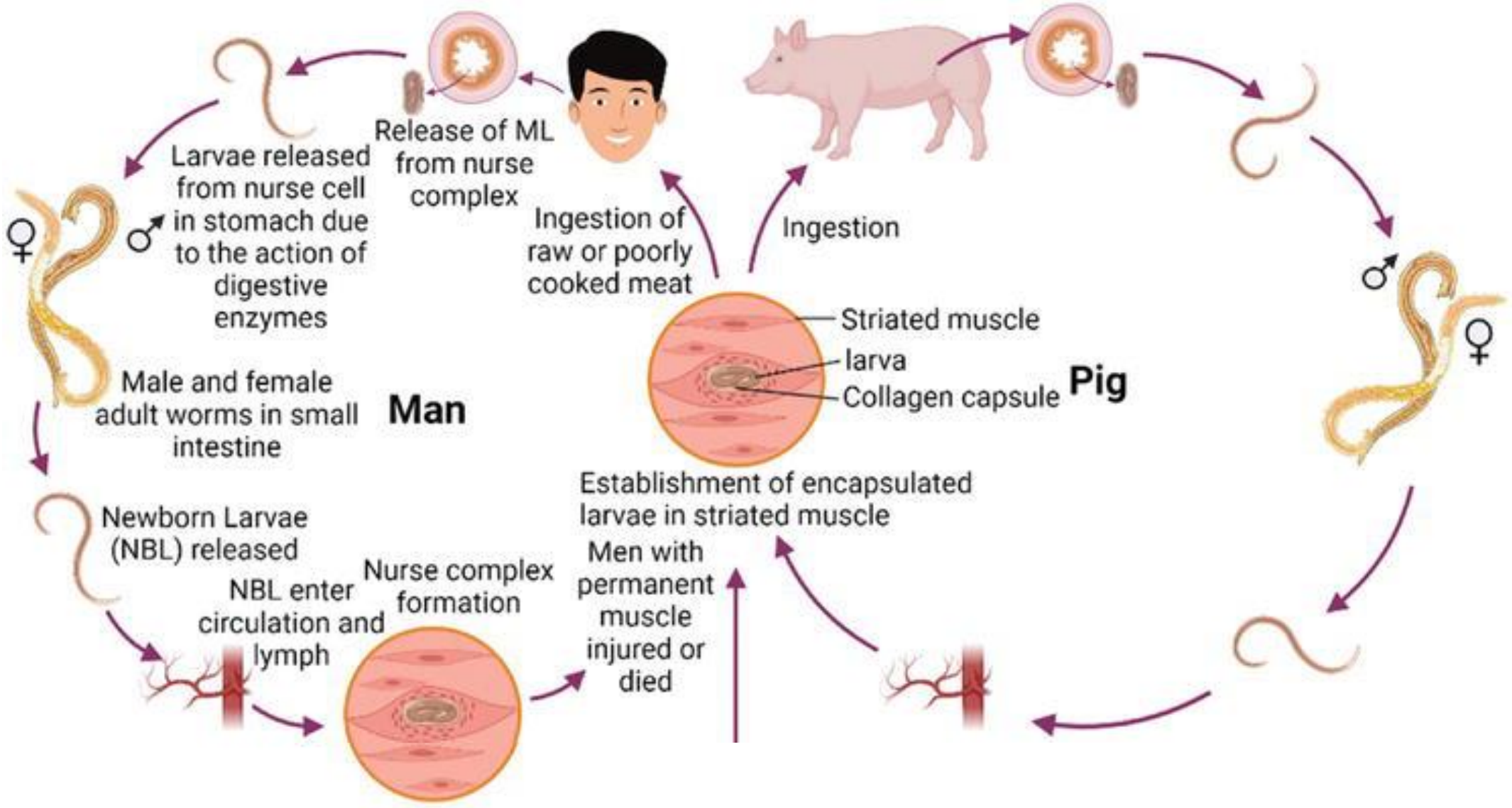

Pathogenesis and clinical picture:

1. Light infection: is usually asymptomatic and self-limiting.
2. Heavy infection: can be considered in 3 successive phases.
   a) **Intestinal phase** (1st week): 24 hours after infection (due to invasion of the intestinal mucosa) there is severe gastro-enteritis, manifested by: Nausea, vomiting, abdominal pain, diarrhea, colic and slight fever (simulating acute food poisoning).
   b) **Migratory or muscle invasion phase** (2nd and 3rd week): due to migration of larvae.
   c) **Encapsulation phase** (end of the third week): Discussed in Muscloskeletal block.

Diagnosis:

A. **Clinical picture** of gastroenteritis in a group of people sharing the same meal (pork meat) is suggestive.

B. **Laboratory:**

1. Direct methods for detection of larvae in muscle biopsy (3-4 weeks after infection) and examined by:

   a) Direct slide technique (trichinoscopy)
   b) Xenodiagnosis

2. Indirect methods

   a) Serological tests: for detection of antibodies and antigens as ELISA and IFAT.
   b) Intradermal test (Bachman's test)

9. *Capillaria philippinensis*
(Intestinal capillariasis)

Disease	Intestinal capillariasis
Geog. distribution	It was discovered in 1963 as a parasite of humans in the Philippines. It was reported also in Thailand, Japan, Iran and recently in Egypt.
Final host Intermediate host	Man and fish eating birds. freshwater fish.
Habitat	Small intestine.
Infective stage	1. Infective larvae in fish gut 2. Thin-shelled egg
Mode of infection	1. Eating raw or undercooked whole fish containing infective larvae in its gut. 2. Internal autoinfection.
Diagnostic stage	Thick-shelled eggs, and larvae

life cycle of *Capillaria philippinensis*

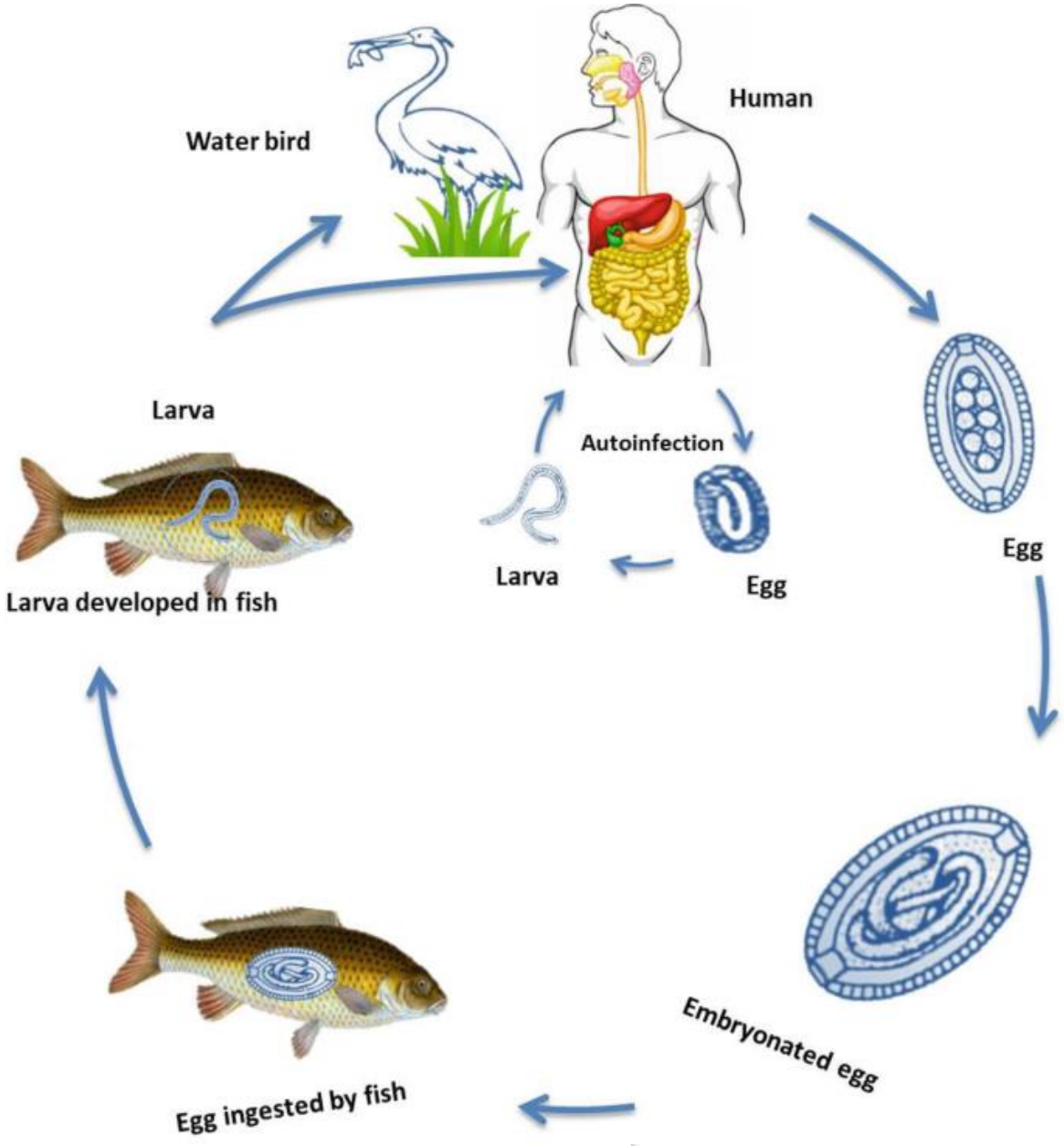

Pathogenicity and clinical picture

1. The worms cause extensive damage of the mucosa with **villous atrophy, resulting in malabsorption syndrome** with diarrhea and abdominal pain.
2. The patients also experience massive weight loss, weakness, malaise, anorexia and emaciation.
3. **Protein and electrolytes especially potassium, sodium and calcium are lost.**
4. The disease progressive and patients die from loss of electrolytes, heart failure or secondary bacterial infection.

Diagnosis:

- ✓ Stool examination reveals the presence of un-embryonated eggs
- ✓ In severe watery diarrhea, larvae and even adults may be found.

Protozoa

1- *Giardia lamblia (Giardia intestinalis)*

Disease	Giardiasis
Host	human (more common in children than adult).
Habitat	Upper part of small intestine (duodenum) and gall bladder.
Infective stage	cyst.
Diagnostic stage	cyst or trophozoite
Mode of infection	Infection occurs by ingestion of the cyst stage (infective stage) with contaminated food or water

Life cycle

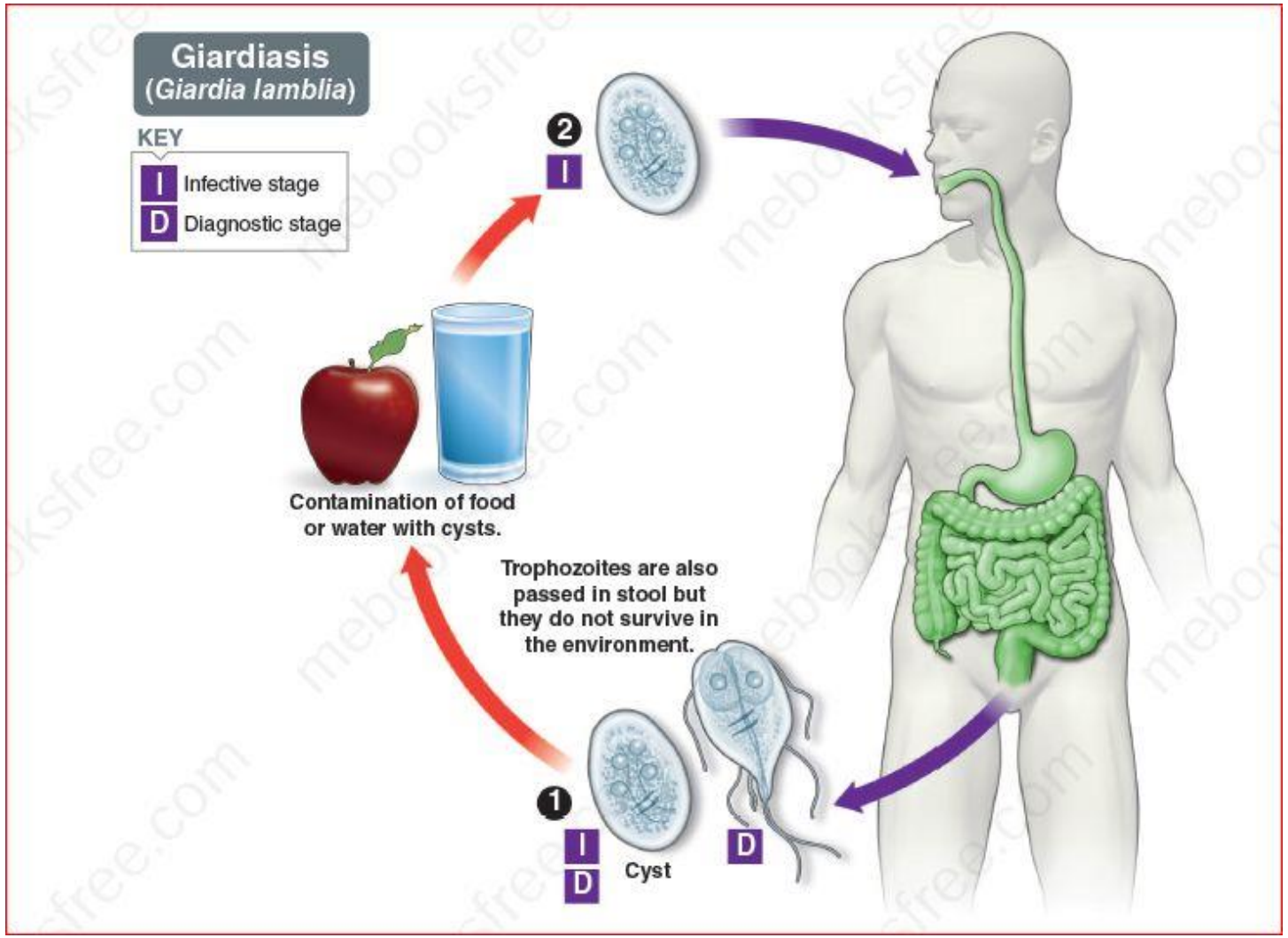
Giardiasis
(Giardia lamblia)
KEY
I Infective stage
D Diagnostic stage
2
I
Contamination of food
or water with cysts.
Trophozoites are also
passed in stool but
they do not survive in
the environment.
1
I
D
Cyst
D

Pathogenesis:

- Attachment of *Giardia* to the mucosal wall with the aid of the sucking disc leads to shortening of villi of small intestine, inflammation of crypts of lamina propria and mucosal lesions. This cause malabsorption of fats and fat-soluble substances and vitaminB12.
- **Stools can therefore be fatty and smelly (steatorrhea).**
- Occasionally bile duct and gallbladder are affected.

Clinical picture:

1. **Acute** with short-lasting diarrhea

- Steatorrhea, sudden explosive, watery diarrhea alternating with bulky, frothy, greasy, foul-smell, no blood or mucus
- Upper gastro-intestinal manifestation, bloating, flatulence, cramps, nausea, vomiting, anorexia. Usually clears spontaneously (undiagnosed), but can persist and become chronic

2. **Chronic** leading to nutritional disorders:

- Intermittent attack of diarrhea (bulky, frothy, greasy, foul-smelling stools)
- Sulfuric belching (rotten egg taste), epigastric pain.
- weight loss and failure to thrive in children.
- "Malabsorption syndrome" such as **steatorrhea and Malabsorption of fat-soluble vitamins.**
- Complication as cholangitis.

Diagnosis:

A. Clinical picture

B. Laboratory Diagnosis

- Routine stool examination: to detect cysts or trophozoite
- Entero-Test capsule or duodenal aspirate can be helpful in recovery of the trophozoites.
- Immunodetection: Antigen detection in stool (coproantigens) using ELISA.
- PCR to detect *Giardia* DNA.

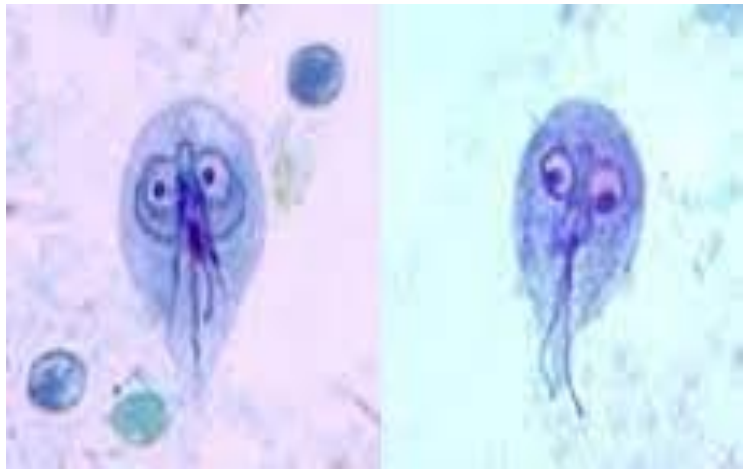

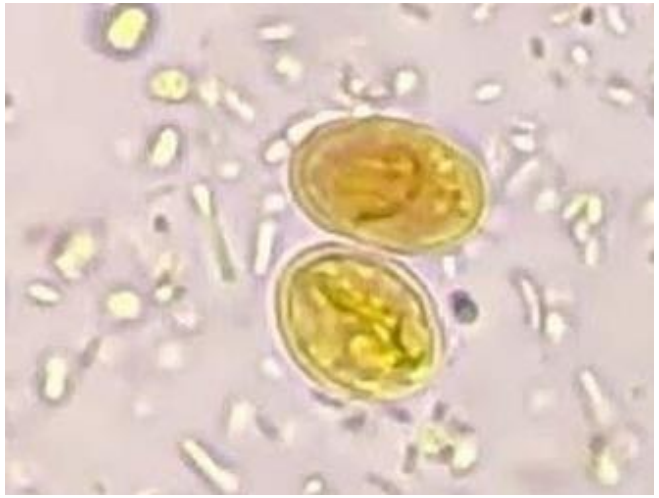

2. Cryptosporidium
C. parvum and C. hominis

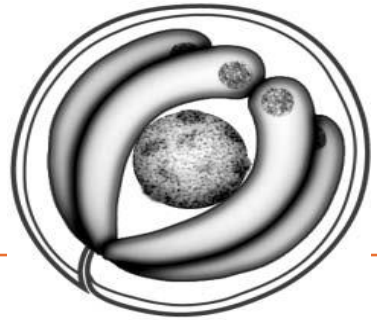

Geog. distribution	World-wide zoonotic disease.
Disease	Cryptospordiosis
Host	Wide range of vertebrate hosts, including man (host nonspecific and zoonotic)
Habitat	brush border of the epithelial cells of intestine, gall bladder and respiratory tract.
Infective stage	Sporulated oocyst containing 4 sporozoites
Diagnostic stage	Sporulated oocyst containing 4 sporozoites
Mode of infection	1. Faecal-oral route by ingestion of thick-walled oocysts in contaminated food or water (not killed by chlorination). 2. Internal autoinfection by thin-walled oocysts, which release sporozoites in situ.

Life cycle: It is divided into three phases, schizogony, gametogony and sporulation. Sporulation takes place within the host.

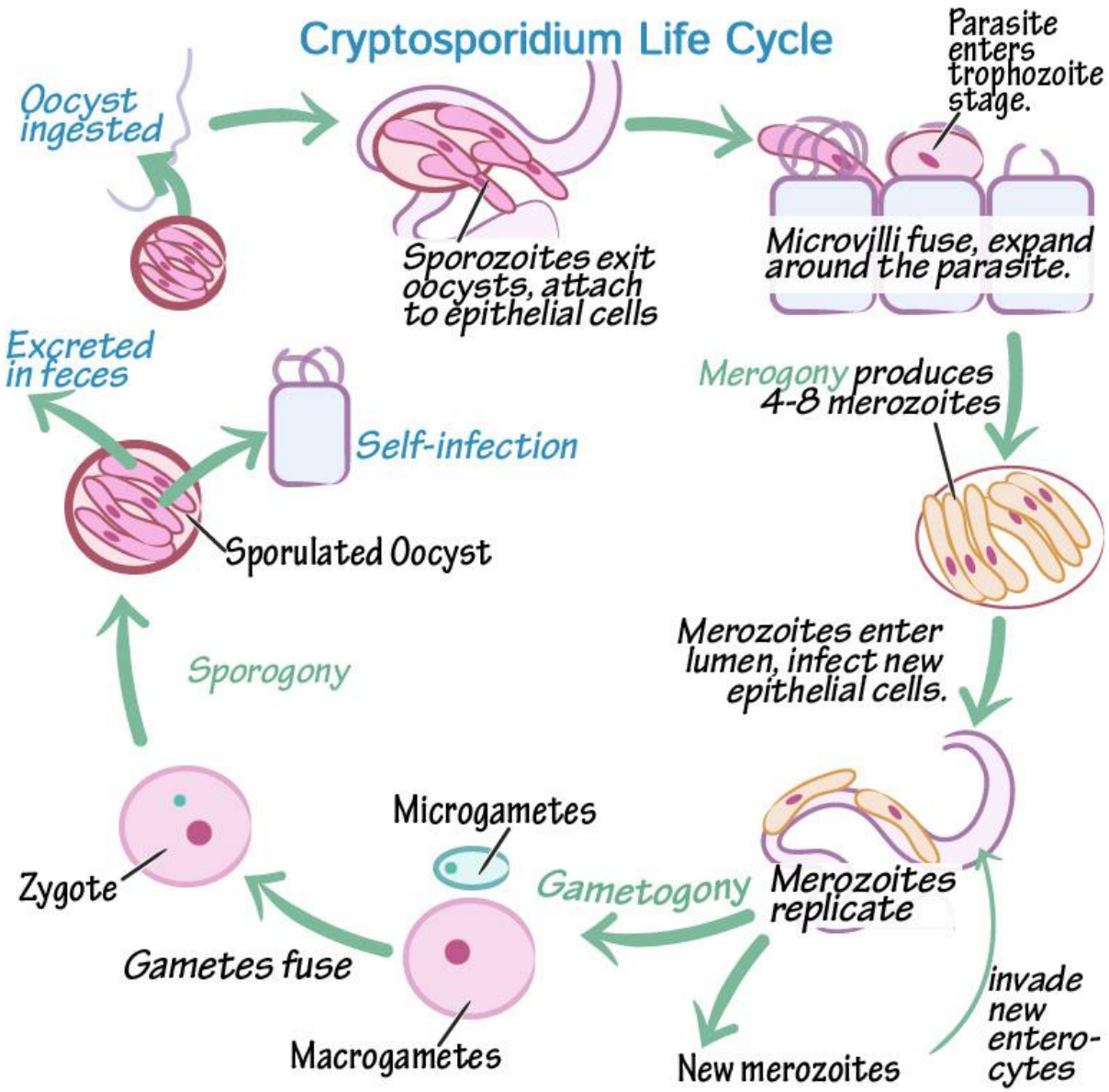

Clinical feature:

- The incubation period is an average of 7 days (range: 2–10 days). Immunocompetent patients may present with self limited diarrheal illness, typically resolving within 2–3weeks.
- Immunocompromised patients may have more severe complications, such as life-threatening malabsorption, dehydration and wasting.
- Extraintestinal cryptosporidiosis (e.g., in the pulmonary or biliary tract, rarely in the pancreas) has been reported.

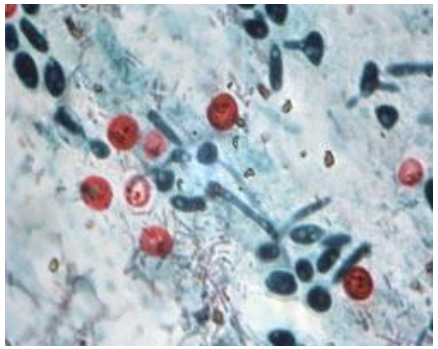

Diagnosis:

1. Oocysts are demonstrated by **using Ziehl-Nielsen stained faecal smears. oocysts appear as red acid-fast spheres, against a blue background**
1. Intestinal biopsy shows dots (cysts) in intestinal glands.
2. Serological by immunofluorescence test.

ANY
QUESTIONS?

Thank you!